

Mahes Visvalingam

Personal Website

Corns & Warts : Thuja, Banana, Aloe Vera, Camphor

Please read the [Disclaimer](#)

Introduction

Please note that there are different types of warts and they may have different causes and cures.

1. My neighbour tapes banana peel on her children's verruca (warts caused by the human papilloma virus) and other warts. But this did not help a friend with plantar warts on the soles of her feet.
2. Thuja alone dried up a crop of flattish warts on the back of someone I know. There were tiny black spots in most of the shrivelled warts, which were still there a year later.
3. We have had some success with (1) **banana peel** (on corns), (2) **Aloe Vera leaf slime** (on corns and burns), and (3) **camphorated vapour rub** on Seborrhic warts. (4) A **[bicarbonate of soda paste](#)** made with coconut oil can also make the warts shrivel and drop off, sometimes with some bleeding. This type of wart has various causes including certain medicines and can disappear when (5) **some medication is discontinued**.

2001 - 2005 : Corns and Warts caused by embedded foreign bodies

In May 2005, Anne Riven - a reflexologist from Dronfield in Derbyshire - suggested banana peel when she saw me limping with pain. I tried taping banana peel to a troublesome corn. The skin around the periphery of the corn became spongy and rubbery by the next morning and it was possible to pick this dead skin off with a sterilised needle. One repeat treatment of the corn almost completely removed it and I was able to wear all my shoes again without pain.

In autumn 2001, I got some splinters into the index finger in my right hand. Since I am right handed and could not get them out, I tried dowsing it with white spirit, vinegar, lemon juice and anything else which I felt might disinfect and rot the wood, and ignored the irritation. But it developed into a cauliflower type wart, which swells and becomes spongy when wetted by showering, washing-up etc. By summer 2004, it reached the size of a pea and was becoming painful when knocked. From time to time the wart would split and bleed.

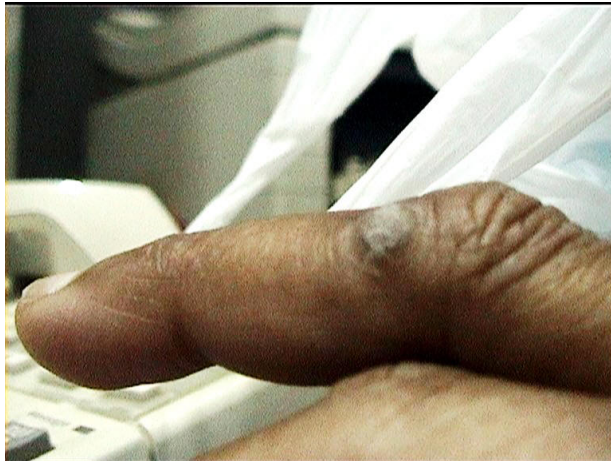I took Biochemic tissue salt Thuja 6x in Sep 2005; this dried up the wart into a hard lump but the wart would re-grow after a while. Someone else tried Thuja and it also changed the appearance of the cluster of warts on his back after a couple of doses but did not eliminate them even after completing a course of treatment. I took nearly 2 bottles of Weleda Thuja 6c before giving it up.

I tried the banana peel treatment on the wart on my finger. Over the course of about a fortnight, there was exfoliation of the skin around the wart and several tiny splinters came up to the surface and they had to be picked off (quite a painful affair with some bleeding since the flesh had grown into the wood).

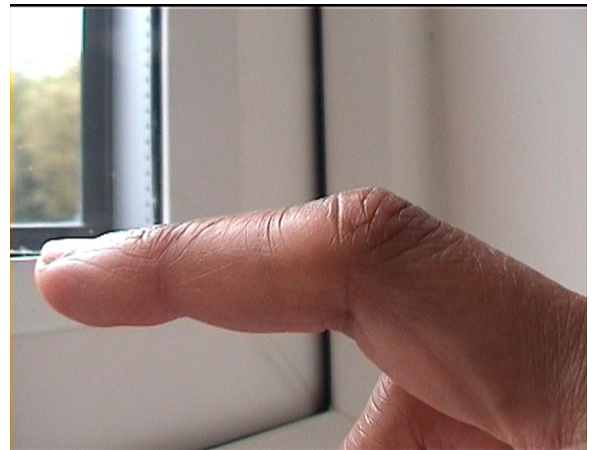
The wart reduced from the size of a pea to that of a split Mysore (orange) lentil and then to a flattened mung bean. At this stage, I went abroad in early Jun 05 and did not treat the wart, which got bigger within a fortnight. The thin skin of Pisang Emas (the little Golden Banana) did not seem to have much of an effect. By 19th Jun, the wart had re-grown into a fissured hard black lump (see photo - 19th June 2005). I tried rubbing it with the skin of a type of banana with a thicker skin similar to that sold in the

UK. This had an immediate effect on the wart - the skin turned whitish especially along the fissures. However, it looks as if neither Thuja nor banana skin can remove warts of this cause on their own.

On return to UK, I took another single dose of 2 pills of Thuja 6x, which dried, reduced and hardened the wart as it had done before. I kept rubbing the wart with banana skin and scratched off the dry skin with my nails. I took one pill of Thuja every fortnight to deter re-growth. By 26th Sept, the wart had nearly gone (see photo 13th Oct). The skin was still discoloured but there was no scarring. All traces of the wart have completely gone.



19th June 2005



13th Oct 2005

Spring 2018 - Seborrhoeic warts

Multiple medications had altered my husband's biochemistry such that he was prone to corns all down the back, the forehead, neck and groin. He was referred to a dermatologist because the wart in the groin looked cancerous. It turned out to be a seborrhoeic wart and the dermatologist removed it by freezing. He said that they do not normally remove warts. [By February 2018](#), we established that the **camphor in vapour rubs** can shrivel and remove this type of wart leaving a discoloured footprint.

Seborrhoeic warts also dry up, crumble and fall off with repeated application of **bicarbonate of soda in coconut** oil (see warts in [BSoda.pdf](#)), leaving a footprint, some of which fade with time.

SUMMARY

Please note that there are different types of warts and they may have different causes and cures.

1. Thuja & banana peel can remove corns and warts when they are caused by grit and splints embedded in the flesh. Unless these are removed, the corns and warts will regrow.
2. Often seborrhoeic warts reappear if they are caused by some medication, as was in my husband's case. When we stopped all medication, many warts went by themselves.

I wanted to test Alternative Therapies and was willing to risk infection with self-treatment. Please see your doctor - troublesome warts/growths can be removed surgically and by safe and pain-free freezing. This process did not leave a scar or footprint.

© Mahes Visvalingam, July 2006

Last updated on 22/12/2021